

CASE STUDY

- 96% WOUND REDUCTION
- TOTAL HEALING IN 1 WEEK
- 1 ACTIGRAFT APPLICATION

PATIENT:

64 Year Old, Male

PAST MEDICAL HISTORY:

Systemic and spinal sepsis

WOUND HISTORY:

- Wound 5 weeks old
- Pressure Ulcer on buttocks
- Heavy exudates

PAST TREATMENTS:

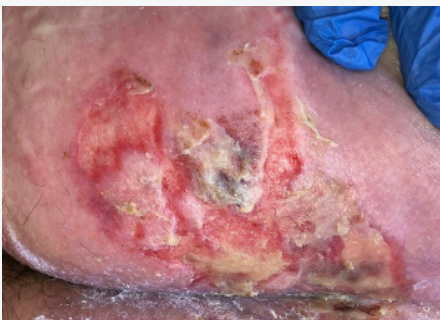Standard of Care

OFFLOADING:

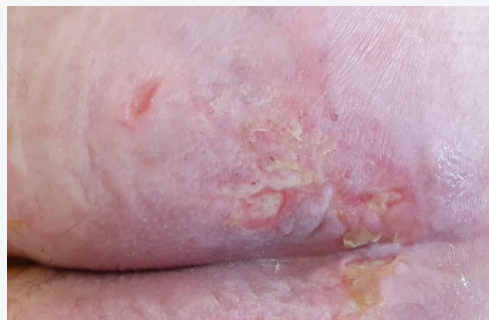Rotated on cushion every few hours

ACTIGRAFT TREATMENT PROGRESSION:

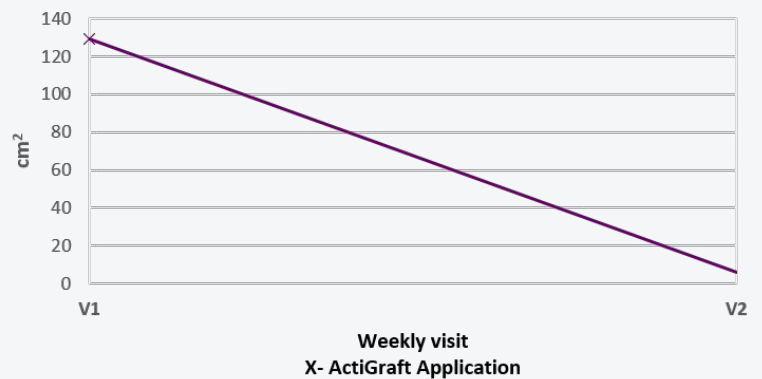
Day 1



Day 7



Wound Area cm²



V=Weekly Application