

CASE STUDY

- 100% WOUND REDUCTION
- TOTAL HEALING IN 8 WEEKS
- 6 ACTIGRAFT APPLICATIONS

PATIENT:

84 Year Old, White Male

PAST MEDICAL HISTORY:

DM2, Chronic Venous Insufficiency, COPD, CHF, IHF, Afib, HL, Dementia

LABS:

HA1C 7.2, H/H 14.9/44.7, 85.4

WOUND HISTORY:

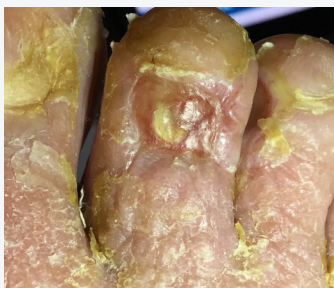- Right 2nd Toe, Full Thickness, Venous Ulcer
- 3 Month Old Ulcer
- 0.9 cm² X 0.1cm, Moderate Serious Drainage
- ABI Results for the Affected Leg = 0.78

PAST TREATMENTS:

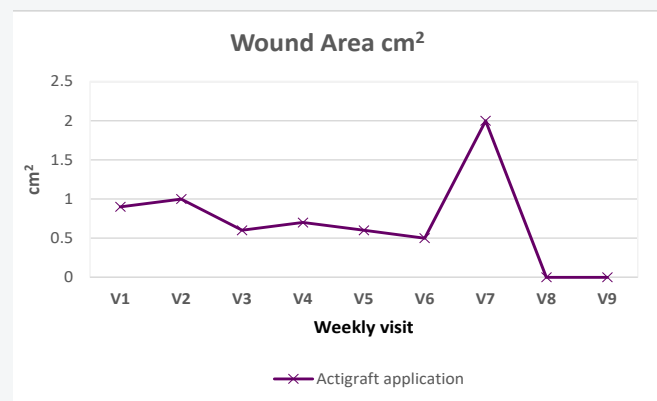
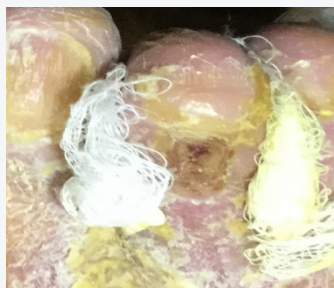Calcium Alginate and Cleansing with Saline Irrigation.
Response To Treatments: None

ACTIGRAFT TREATMENT PROGRESSION:

Day 1



Day 49



V=Weekly Application

OFFLOADING:

None