

CASE STUDY

PATIENT:

69 year-old, male.

WOUND HISTORY:

- 9 month old wounds
- Wounds caused due to trauma in March 2019
- MRSA infection diagnosed in June 2019 and treated with Doxycycline
- Experienced persistent and sharp pain, especially when walking, used pain killers on a regular basis

PAST MEDICAL HISTORY:

Diabetic Mellitus Type 2

PAST TREATMENTS:

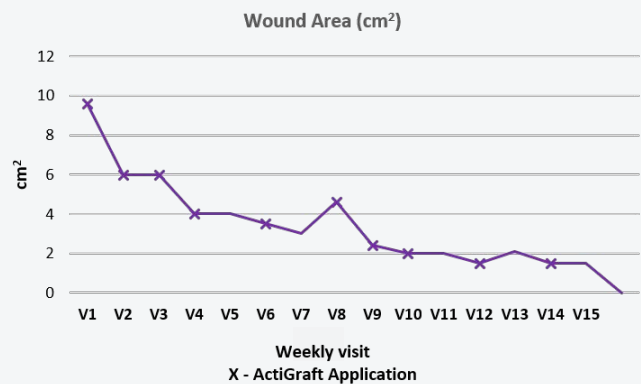
Ultra-MIST treatment – thrice weekly and topical European Wound Gel, Allicin

OFFLOADING:

Boot

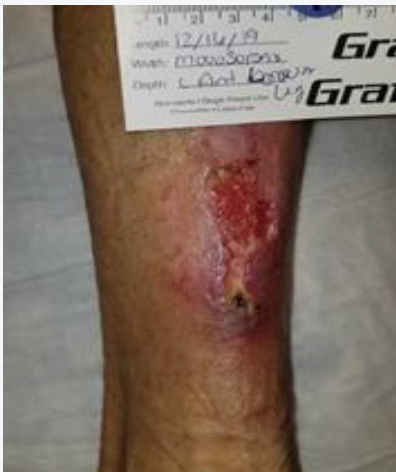LOWER LEG

- 100% WOUND REDUCTION
- TOTAL HEALING IN 15 WEEKS
- 10 ACTIGRAFT APPLICATIONS

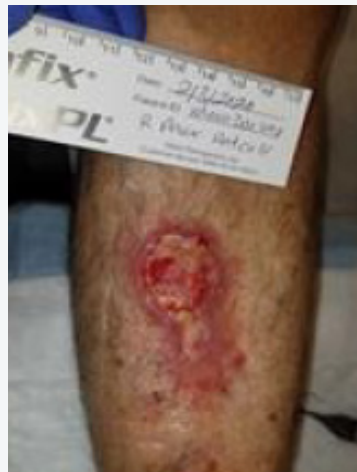

ACTIGRAFT TREATMENT PROGRESSION:

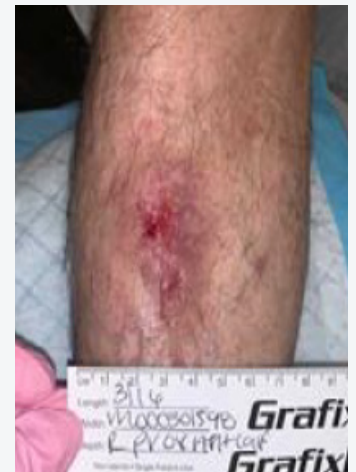Day 0



Day 49

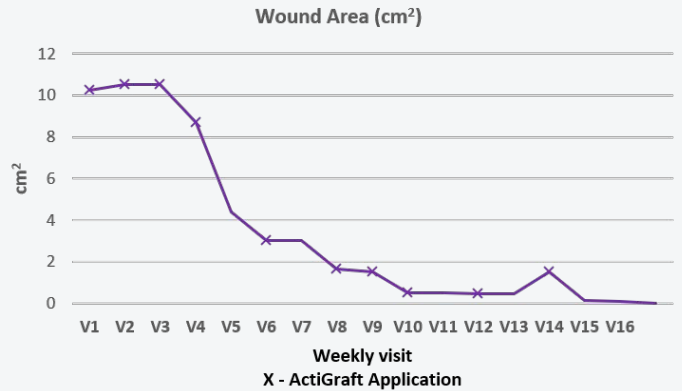


Day 91



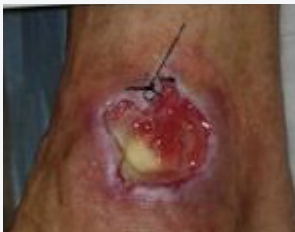ANKLE

- 100% WOUND REDUCTION
- TOTAL HEALING IN 16 WEEKS
- 10 ACTIGRAFT APPLICATIONS

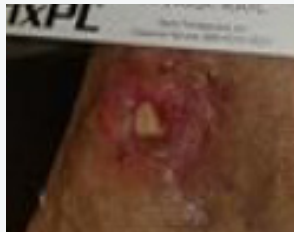

ACTIGRAFT TREATMENT PROGRESSION:

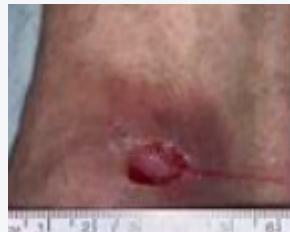Day 0



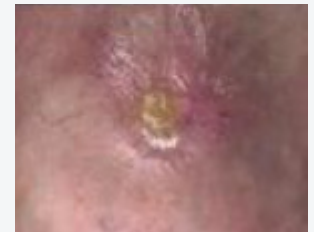Day 49



Day 91

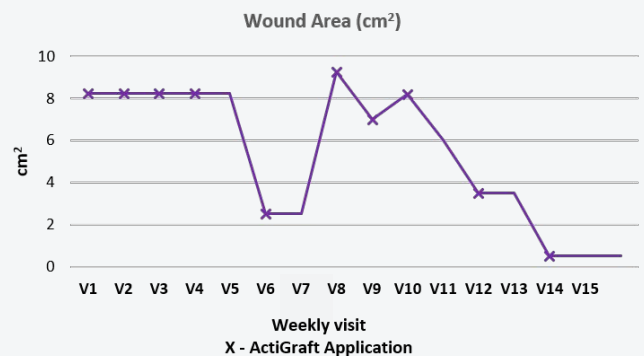


Day 127



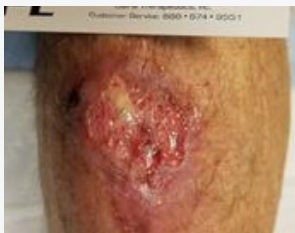CALF

- 100% WOUND REDUCTION
- TOTAL HEALING IN 15 WEEKS
- 10 ACTIGRAFT APPLICATIONS

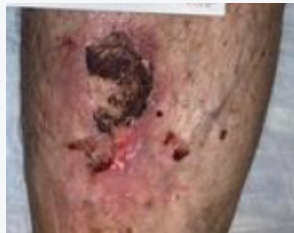

ACTIGRAFT TREATMENT PROGRESSION:

Day 0



Day 64



Day 91

