

## CASE STUDY

- 100% WOUND REDUCTION
- TOTAL HEALING IN 7 WEEKS
- 7 ACTIGRAFT APPLICATIONS

### PATIENT:

50 year-old, Female.

### PAST MEDICAL HISTORY:

DM2

### WOUND HISTORY:

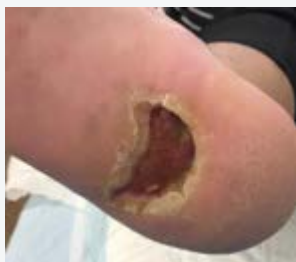- DFU on right heel previous abscess Repeated infections of the foot

### PAST TREATMENTS:

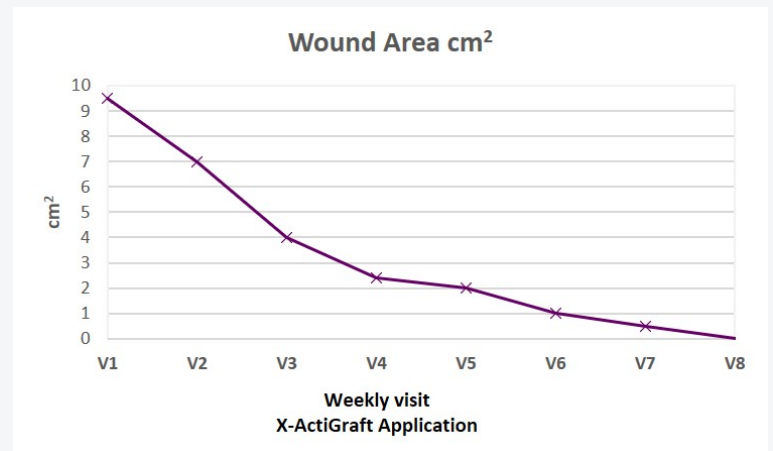
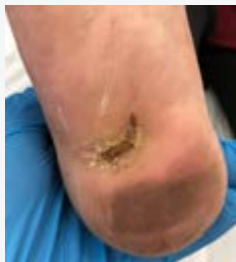VAC, Surgical debridement X3, Silvercel, Advanced dressings, Antibiotics

### ACTIGRAFT TREATMENT PROGRESSION:

Day 0



Day 49



V=Weekly Application

### OFFLOADING:

N/A