

CASE STUDY

- 75% WOUND REDUCTION IN 6 WEEKS
- 3 YEAR OLD WOUND
- 6 ACTIGRAFT APPLICATIONS

PATIENT:

48 Year Old, Female

PAST MEDICAL HISTORY: Obesity, Diabetes, Broken hip with repeated hip replacements in the past 3 years. last replacement 3 years ago

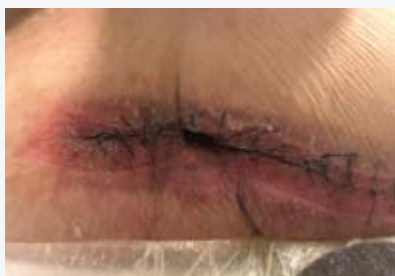WOUND HISTORY:

- Non-healing dehiscence wound on the right upper thigh, due to repeated hip replacements resulted in chronic severe infections of the replacement site.

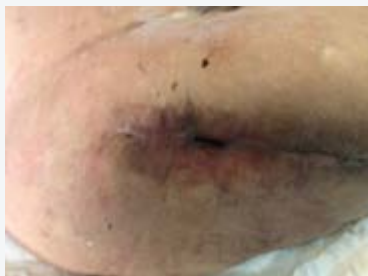PAST TREATMENTS: VAC X 5, re-surgery, long term antibiotics and more advanced treatments with no improvement

ACTIGRAFT TREATMENT PROGRESSION:

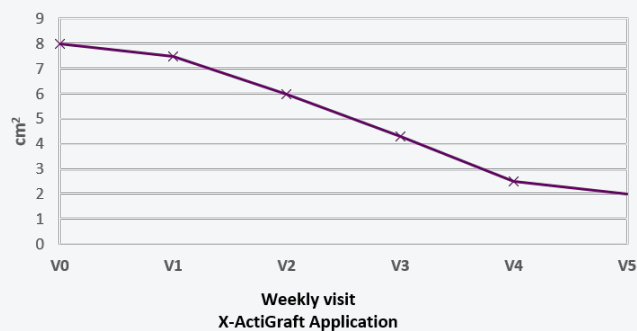
Week 1



Week 6



Wound Area cm²



V=Weekly Application