

## CASE STUDY

- 98% WOUND REDUCTION IN 17 WEEKS
- 16 ACTIGRAFT APPLICATIONS

### PATIENT:

87 Year Old, Male

### PAST MEDICAL HISTORY:

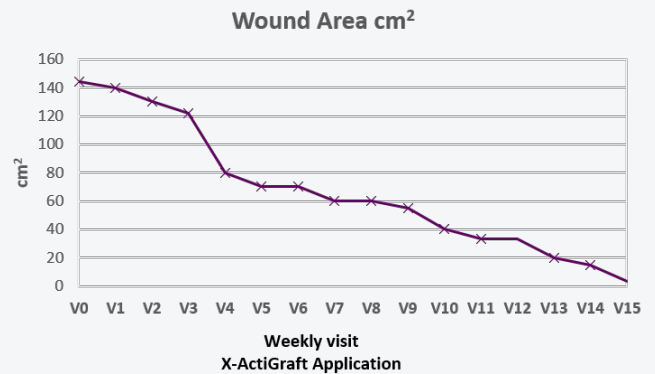
Venous Insufficiency, Controlled diabetes 2, Hypertension

### WOUND HISTORY:

- VLU on calf and shin, heavy exudating

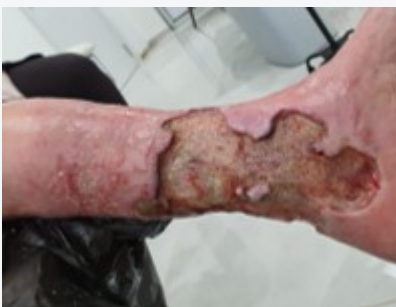### PAST TREATMENTS:

Ozone gas treatment for 4 years- deterioration  
Advanced wound dressings for past 2 years



### ACTIGRAFT TREATMENT PROGRESSION:

Week 1



Week 17

