

CASE STUDY

- 100% WOUND REDUCTION IN 7 WEEKS
- 7 ACTIGRAFT APPLICATIONS

PATIENT:

75 Year Old, Male

PAST MEDICAL HISTORY:

N/A

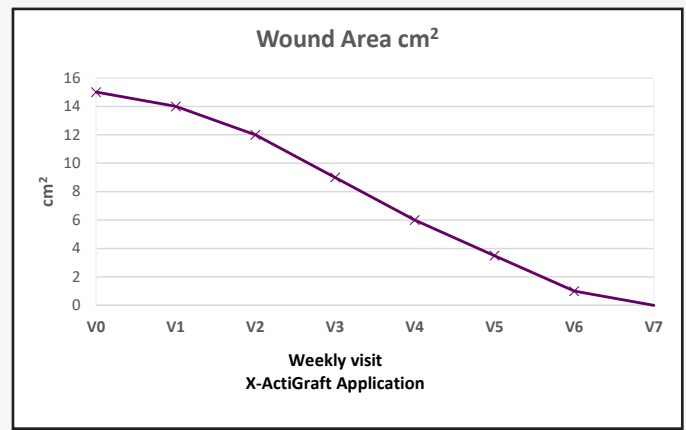
WOUND HISTORY:

- 5-month-old wound; Hypertension, obesity, previous laryngectomy with tracheostomy for laryngeal tumor

PAST TREATMENTS:

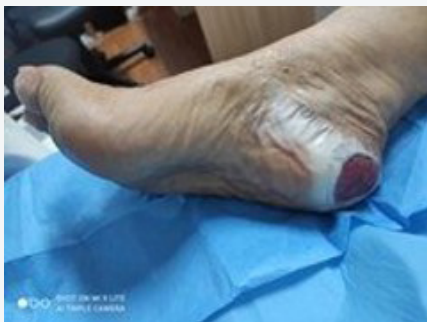Chemical and physical debridement with collagenase and hydro-ozone therapy

ACTIGRAFT TREATMENT PROGRESSION:



V=Weekly Application

Week 1



Week 7

