

CASE STUDY

- 99% WOUND REDUCTION
- 2 ACTIGRAFT APPLICATIONS

PATIENT:

60 Year Old, Male

PAST MEDICAL HISTORY:

T2DM

WOUND HISTORY:

- Plantar DFU with chronic osteomyelitis of ray 1 in the affected foot

PAST TREATMENTS:

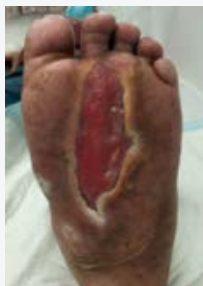VAC, Advanced dressings

OFFLOADING:

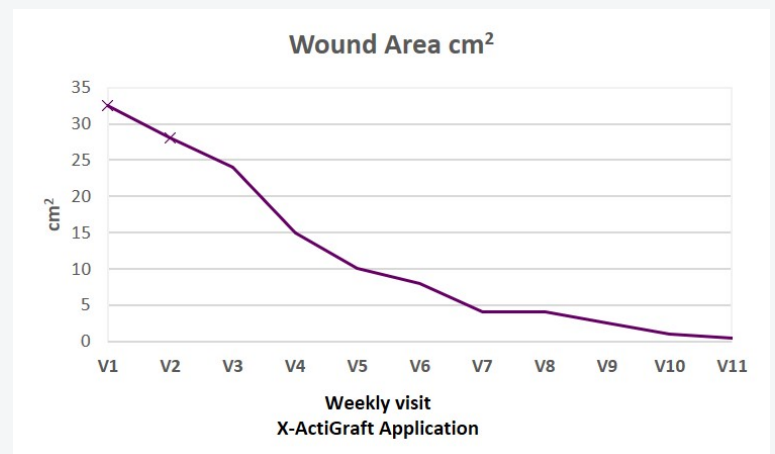
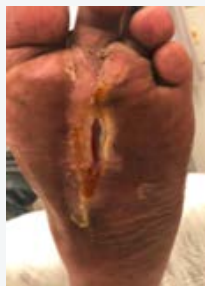None

ACTIGRAFT TREATMENT PROGRESSION:

Day 1



Day 71



V=Weekly Application