

CASE STUDY

- 96% WOUND REDUCTION IN 6 WEEKS
- 5 MONTH OLD WOUND
- 5 ACTIGRAFT APPLICATIONS

PATIENT:

48 Year Old, Male

PAST MEDICAL HISTORY:

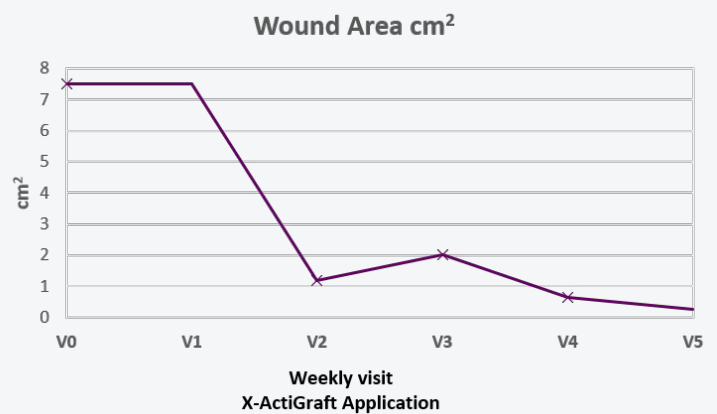
Diabetes Type 2

WOUND HISTORY:

- Dorsal DFU with a tunnel crossing to the ventral foot

PAST TREATMENTS:

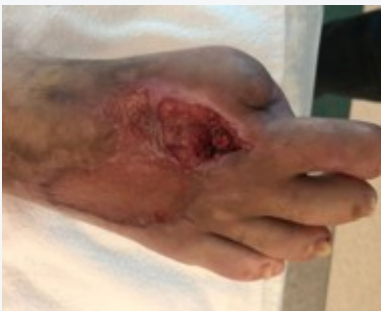n/a



V=Weekly Application

ACTIGRAFT TREATMENT PROGRESSION:

Week 1



Week 6

