

## CASE STUDY

- 100% WOUND REDUCTION
- TOTAL HEALING IN 10 WEEKS
- 7 ACTIGRAFT APPLICATIONS

### PATIENT:

71 year-old, paraplegic male.

### PAST MEDICAL HISTORY:

DM2, Neuropathy, HTN, Anemic, OA, Paraplegic.

### LABS

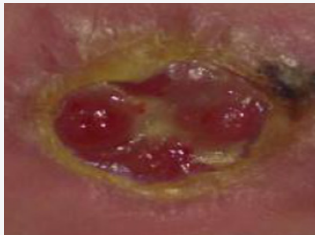
Labs 5/30/14 - HbA1C 8.6, RBC 4.21, HGB/HCT 37, Platelet 92, PTT 22.9.

### WOUND HISTORY:

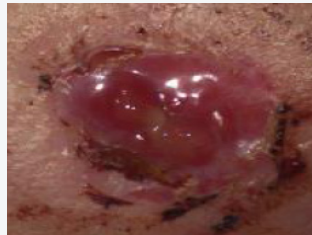
- Diabetic Ulcer 2A right medial foot
- 30 week-old ulcer
- 2.40 cm<sup>2</sup> X 0.3 cm, draining small amounts of serous/sanquinous
- ABI results for the affected leg = 0.90

### ACTIGRAFT TREATMENT PROGRESSION:

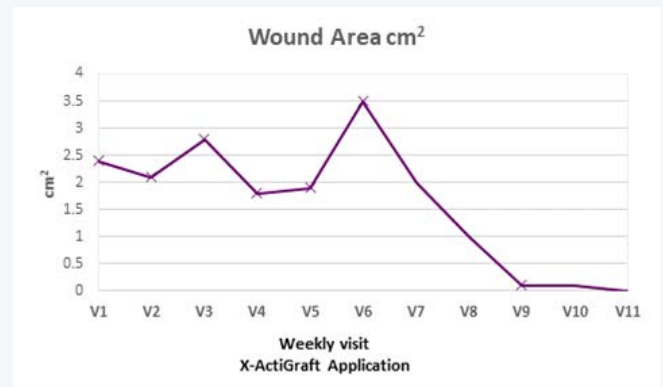
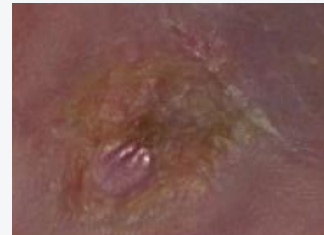
Day 0



Day 35



Day 77



### PAST TREATMENTS:

Wet-to-dry, foam, silver alginate, antibacterial agents, HBO.

### OFFLOADING:

Wheel chair bound.