

OPEN

Diseases of the Colon & Rectum Publish Ahead of Print

DOI: 10.1097/DCR.0000000000003190

ORIGINAL CONTRIBUTION

A Prospective, Single-Arm Study to Evaluate the Safety and Efficacy of RD2-Ver.02, an Autologous Blood Clot, in the Treatment of Anal Fistula

Running Head: Autologous blood clot for anal fistula

Edward Ram, M.D.¹ • Yaniv Zager, M.D.¹ • Dan Carter, M.D.² • Olga Saukhat, M.D.³ • Roi Anteby, M.D.¹ • Ido Nachmany, M.D.¹ • Nir Horesh, M.D.¹

1 Department of General Surgery B and Transplantation, Sheba Medical Hospital Center, Tel Hashomer, Ramat Gan, Israel

2 Department of Gastroenterology, Sheba Medical Center, Tel Hashomer, Ramat Gan, Israel

3 Department of Radiology, Sheba Medical Center, Tel Hashomer, Ramat Gan, Israel

Funding/Support: None reported.

Financial Disclosures: Edward Ram is a consultant at RedDress Ltd.

Presented at the Annual Scientific Meeting for the American Society of Colon and Rectal Surgeons, Seattle, WA, June 3 to 6, 2023.

Correspondence: Nir Horesh, M.D., Department of General Surgery B and Transplantation, Sheba Medical Hospital Center, T Sheba Road 1, el Hashomer, Ramat Gan, 52621

Israel. Email: nir_horesh@hotmail.com

This is an open-access article distributed under the terms of the Creative Commons Attribution-Non Commercial-No Derivatives License 4.0 (CCBY-NC-ND), where it is permissible to download and share the work provided it is properly cited. The work cannot be changed in any way or used commercially without permission from the journal

ACCEPTED

ABSTRACT

BACKGROUND: Surgical treatment of complex perianal fistula is technically challenging, associated with risk of failure, and may require multiple procedures. In recent years, several biologic agents have been developed for the purpose of permanently eradicating anal fistulous disease with variable success. RD2-Ver.02 treatment is an autologous whole blood product created from the patients' blood, which forms a provisional matrix that was found to be safe and effective in healing acute and chronic cutaneous wounds.

OBJECTIVE: To assess the efficacy and safety of RD2-Ver.02 as a treatment for transsphincteric perianal fistulas.

DESIGN: A prospective single-arm study.

SETTINGS: A single tertiary medical center.

PATIENTS: Patients with simple or complex transsphincteric fistulas confirmed by magnetic resonance imaging were included in the study. Etiology was either cryptoglandular or Crohn's related (in the absence of active luminal bowel disease).

INTERVENTION: The outpatient procedure was performed under general anesthesia and consisted of: 1) physical debridement and cleansing of the fistula tract; 2) suture closure of the internal opening; and 3) instillation of RD2-Ver.02 into the entire tract.

MAIN OUTCOME MEASURES: Safety and efficacy at 6- and 12-months following surgery.

RESULTS: Fifty-three patients (77% male) with a median age of 42 (20-72) years were included in the study. Three patients withdrew consent, and 1 patient was lost to follow-up. At the time of this interim analysis, 49 and 33 patients completed the 6 and 12 months follow-up period, respectively. Thirty-four (34) patients achieved complete healing (69%) at 6 months while 20 patients out of 33 (60%) achieved healing after 1 year. All patients who achieved

healing at 6 months remained healed at the 1 year mark. In a subgroup analysis of Crohn's patients, 7 of 9 patients completed 1-year follow-up, with 5 patients (71%) achieving clinical remission. No major side effects or postoperative complications were noted, while 2 adverse events occurred (admission for pain control and COVID-19 infection).

LIMITATIONS: Noncomparative single-arm pilot study.

CONCLUSIONS: Treatment with RD2-Ver.02 in perianal fistular disease was found to be feasible and safe, with an acceptable healing rate in both cryptoglandular and Crohn's fistula in ano. Further comparative assessment is required to determine its potential role in the treatment paradigm of fistula-in-ano. See **Video Abstract**.

UN ESTUDIO PROSPECTIVO DE UN SOLO BRAZO PARA EVALUAR LA SEGURIDAD Y EFICACIA DE RD2-VER.02, UN COÁGULO DE SANGRE AUTÓLOGO, EN EL TRATAMIENTO DE LA FÍSTULA ANAL

ANTECEDENTES: El tratamiento quirúrgico de la fístula perianal compleja es técnicamente desafiante, se asocia con riesgo de fracaso y puede requerir múltiples procedimientos. En los últimos años, se han desarrollado varios agentes biológicos con el fin de erradicar permanentemente la enfermedad fistulosa anal con éxito variable. El tratamiento RD2-Ver.02 es un producto de sangre total autólogo creado a partir de la sangre de los pacientes, que forma una matriz provisional que resultó segura y eficaz para curar heridas cutáneas agudas y crónicas.

OBJETIVO: Evaluar la eficacia y seguridad de RD2-Ver.02 como tratamiento para las fístulas perianales transesfinterianas.

DISEÑO: Un estudio prospectivo de un solo brazo.

LUGARES: Un único centro médico terciario.

PACIENTES: Se incluyeron en el estudio pacientes con fístulas transesfinterianas simples o complejas confirmadas mediante resonancia magnética. La etiología fue criptoglandular o relacionada con la enfermedad de Crohn (en ausencia de enfermedad intestinal luminal activa).

INTERVENCIÓN: El procedimiento ambulatorio se realizó bajo anestesia general y consistió en: 1) desbridamiento físico y limpieza del trayecto fistuloso; 2) cierre con sutura de la abertura interna; y 3) instilación de RD2-Ver.02 en todo el tracto.

PRINCIPALES MEDIDAS DE RESULTADO: Seguridad y eficacia a los 6 y 12 meses después de la cirugía.

RESULTADOS: Se incluyeron en el estudio 53 pacientes (77% varones) con una mediana de edad de 42 (20-72) años. Tres pacientes retiraron su consentimiento y un paciente se perdió durante el seguimiento. En el momento de este análisis intermedio, 49 y 33 pacientes completaron el período de seguimiento de 6 y 12 meses, respectivamente. Treinta y cuatro (34) pacientes lograron una curación completa (69%) a los 6 meses, mientras que 20 de 33 pacientes (60%) lograron una curación después de un año. Todos los pacientes que lograron la curación a los 6 meses permanecieron curados al año. En un análisis de subgrupos de pacientes con enfermedad de Crohn, 7/9 pacientes completaron un seguimiento de un año y 5 pacientes (71%) alcanzaron la remisión clínica. No se observaron efectos secundarios importantes ni complicaciones postoperatorias, mientras que ocurrieron 2 eventos adversos (ingreso para control del dolor e infección por COVID-19).

LIMITACIONES: Estudio piloto no comparativo de un solo brazo.

CONCLUSIONES: Se encontró que el tratamiento con RD2-Ver.02 en la enfermedad fístula perianal es factible y seguro, con una tasa de curación aceptable tanto en la fístula criptoglandular como en la de Crohn en el ano. Se requiere una evaluación comparativa adicional para determinar su papel potencial en el paradigma de tratamiento de la fístula anal. (*Pre-proofed version*)

KEY WORDS: Autologous blood clot; Crohn's disease; Perianal fistula; Surgical outcomes.

ACCEPTED

INTRODUCTION

Anal fistulas (AF) are a common and frequently disabling medical disorder that affects millions of people worldwide. They occur when aberrant drainage tracts connect the anal canal and rectum with the skin around the anus. AF, which are classified based on their anatomical location and the relation to the external sphincter muscles, can be simple or complex.¹ Transsphincteric fistulas (TSF), which are the second most common type of perianal fistulas, can also be classified as complex, if they involve over 30% of the external sphincter muscle, high fistulas and fistulas associated with inflammatory bowel disease among other parameters.¹⁻⁵

The main factors affecting the ability to successfully manage AF are fistulas with multiple tracts, persistence of inflammation due to untreated sepsis or granulation tissue, inability to accurately locate and close internal openings, or active Crohn's disease. Despite multiple attempts at refining surgical management, recurrence rates remain unacceptably high for both cryptoglandular and Crohn's related AF.⁶

Surgical treatment remains the standard of care for perianal fistular disease.⁷ A fistulotomy is highly successful for simple transsphincteric fistulas, however even this procedure risks some damage to the external anal sphincter and subsequent incontinence. Complex AF, by definition involves >30% of the external sphincter muscle, rendering treatment far more challenging both in terms of successful eradication and fecal continence.⁸ The proliferation of surgical procedures and technologies is evidence of these challenges, however both recurrence rates and incontinence rates have contributed to the lack of a universally accepted surgical approach.⁹ This is particularly true in Crohn's-related AF where success is even lower.¹⁰

Recently, efforts have shifted to various biologic products including fibrin glue, mesenchymal and adipose-derived stem cells with the hope of avoiding anal sphincter injury while

permanently occluding the fistula tract.¹¹ However, robust clinical trials have produced only moderate success rates despite significant treatment costs. The result is that these biologic interventions are often restricted to very specific patient populations.¹¹

RD2-Ver.02 (RedDress Ltd, Pardes Hannah-Karkur, Israel) is an autologous whole blood clot treatment, created from the patient's peripheral blood at the time of the procedure.¹² The treatment was found to be safe and effective in acute and chronic soft tissue wounds.¹³⁻¹⁷ The blood clot product is applied to the entire wound surface, thus creating a temporary scaffold and matrix to facilitate tissue healing.¹⁸

In this study, we aimed to explore the safety and efficacy of RD2 Ver.02 treatment for the purpose of closure of simple and complex transsphincteric anal fistula.

MATERIALS AND METHODS

Study Design

This report is an interim analysis of an open label, prospective pilot study which aimed to examine the safety and efficacy of RD2-Ver.02 in patients suffering from transsphincteric anal fistula. The study was performed in a large tertiary medical center in Israel (Sheba Medical Center). The study was initiated in April 2021, and is currently ongoing. The study was approved by the hospital's Ethics Committee (approval # 7731-20). All the subjects enrolled in the study provided informed consent.

Study Participants

The study population consisted of subjects aged ≥ 18 years with transsphincteric perianal fistula, confirmed by a preoperative Magnetic Resonance Imaging (MRI). Sixty (60) patients were screened for the study. Seven (7) patients were excluded from the study after MRI determined the presence of an intersphincteric fistula amenable to fistulotomy (see inclusion criteria below)

(Fig. 1). Fifty-three patients who met the inclusion criteria were enrolled in the study and received the study procedure and RD2-Ver.02 treatment. Inclusion criteria included patients ≥ 18 years old with transsphincteric cryptoglandular or Crohn's-related anal fistula confirmed by MRI. Patients on anti-platelet or oral anticoagulants were eligible. Patients with prior failed attempts at fistula closure were also allowed. Exclusion criteria included patients with active luminal inflammatory bowel disease involving any portion of the gastrointestinal tract, any malignancy, life expectancy of < 24 months, prior medical history of coagulation disorders and/or abnormal platelet function, prolonged PT/PTT, and systemic steroids. Patients with IBD were excluded if they were suffering from any abdominal / extraintestinal symptoms or were actively treated for these symptoms by their gastroenterologist.

Simple fistulas were categorized as transsphincteric AF with $\leq 30\%$ of the external sphincter, while complex fistulas were defined as AF with $> 30\%$ of the external sphincter, high transsphincteric fistulas (with or without a high blind tract), or horseshoe fistulas, based on the 2022 American Society of Colon and Rectal Surgeons guidelines for treatment of fistula in ano.^{7,19}

The Procedure

The procedure in the study was performed in an outpatient setting. Patients without a prior colonoscopy within two years from a surgical intervention, were recommended to undergo a screening colonoscopy prior to surgery. The study procedure was performed under general anesthesia and the surgical steps were: 1) debridement and cleansing of the fistula using a fistula brush and hydrogen peroxide, followed by saline rinsing to remove any remains of hydrogen peroxide; 2) suture closure of the internal fistula opening, confirmed by water leak test; and 3) instillation of the RD2-Ver.02 preparation.

Eighteen (18) mL of blood was drawn from the patient for the RD2-Ver.02 preparation. The blood was collected in acid citrate dextrose adenine (ACDA) vacuum tubes, and was transferred to the activation mold containing calcium gluconate (50 mg) and kaolin (28 mg) powders (RedDress, Pardes Hannah-Karkur, Israel) for activation *ex vivo*. The RD2-Ver.02 preparation was instilled during withdrawal from the fistula tract of a 14G Angiocath IV catheter from the closed internal opening to the external fistula opening. The operative field is observed for approximately 5 minutes to assure coagulation of the RD2-Ver.02 preparation within the fistula tract (Fig. 2). A video of the procedure can be seen in the supplement files (video supplement 1 at <https://links.lww.com/DCR/CXX>).

Postoperatively, patients were given oral antibiotics (ciprofloxacin 500 mg BID + metronidazole 500 mg TID for 7 days) and were prescribed stool softeners (sodium picosulfate 30 g daily for a week), both based on the surgeon's discretion.

Patients were followed at the clinic at 1 week, 2 weeks, 1 month, 2 months, 3 months, and 6 months after the procedure. Long-term follow-up is to be conducted 12 months after the procedure.

Healing/Remission Assessment of the Fistula

Clinical efficacy was assessed using fistula clinical symptoms compared to baseline. Fistula clinical symptoms included: discharge from the fistula, healing/remission of fistula tract and external opening, as determined by the investigator at the follow-up visits.

The symptoms were graded on a scale of: deterioration, no improvement, minor improvement, medium improvement, and significant improvement. Complete healing/remission was defined as the absence of any anal symptoms, including pain and discharge from the fistula, and a clinically confirmed closed external opening, which were validated with a postoperative MRI.

Postoperative MRI was performed at 6 months in all patients. Healing at 12 months was evaluated clinically.

Study Outcomes

The primary endpoint was healing rate by 6 months of anal fistulas treated with RD2-Ver.02, defined as the absence of any anal symptom, with no discharge from the fistula and a closed external opening confirmed on clinical evaluation and a postoperative MRI was performed at 6 months in all evaluated patients.

Safety endpoint was evaluated by the overall incidence and severity of Adverse Events, based on Common Terminology Criteria for Adverse Events Version 5 (CTCAE v.5 grading).⁵

RESULTS

A total of 53 patients met the inclusion criteria and underwent the study procedure. Four (4) patients did not complete follow-up) 3 withdrew informed consent prior to the follow-up portion of the study and one was lost to follow-up) (Fig. 2). All patients who underwent the study procedure were included in the safety analysis. However, the data presented in the interim efficacy data at 6 months, is presented as per protocol (PP) for those who participated in the postoperative follow-up regimen, and as intent to treat (ITT) for all patients, regardless of their adherence to the follow-up regimen. The study demographic and clinical data are demonstrated in Table 1. The majority of patients were male with a median age of 42 (range, 20-72) years and had cryptoglandular AF (n = 44, 83%). MRI findings diagnosed 19 patients (36%) as simple and 34 patients (64%) as complex AF. Twenty-five (25) patients (47%) had a seton present while they underwent the procedure, for a duration of at least 6-8 weeks prior to the procedure. The seton was removed at the time of the procedure. 40% of patients had failed other interventions ranging from 2-6 prior treatments prior to the procedure including fistulectomy (n = 7; 13%); or

ligation of intersphincteric fistula tract (LIFT) (n = 4, 8%). The mean operative time was 25±3 minutes.

Interim Results Analysis

At the time of this interim analysis, 49 patients have reached the 6-month follow up and 33 have reached 1-year follow-up (Fig. 2). At 6 months follow-up, 34 patients (69%) were healed following RD2-Ver.02 treatment. At 1 year, 20 subjects have reached complete healing (61%). All the patients who achieved healing at 6 months remained healed at one year. A total of 20 patients presented with multiple tracts, while 13 patients had multiple openings and multiple tracts at the time of the procedure. Among the patients with multiple tracts, 13/20 (65%) have healed by 6 months. As for the group of patients with both multiple openings and tracts, 9/13 (69%) healed by the 6-month timeframe. Stratifying for the complexity of the fistula, demonstrated that 23/ 34 (68%) complex AF's were healed after 6 months, similar to the outcome for simple AF (11/19; 58%). An example of a patient with a complex fistula who achieved fistula healing can be seen in Figure 3. Kaplan-Meier analysis demonstrated that the median duration of success was 379 days (95% CI, 354.8-403.1).

Crohn's Disease Patients

Nine (9) patients with perianal Crohn's disease were enrolled in the study. At the time of enrollment, 8 patients were on maintenance treatment with biological therapy for their Crohn's disease without evidence of active gastrointestinal disease. At the time of this analysis, all 9 patients have reached the 6-month follow-up while 7 of them have reached the 12-month follow-up time point.

At the 6-month follow-up, 6 of 9 patients (67%) were healed, 1 patient showed progression towards healing and 2 patients were considered initial treatment failures. At the 1-year mark, 5/6 ultimately remained healed (83%) and 1 patient failed at 1 year.

Safety

There were no device-related adverse events (DRAE). There were a total of 15 adverse events (AEs) of which 2 were serious adverse events (SAEs). The first SAE was hospitalization due to COVID-19 and was not related to the device or the study. The second SAE was hospitalization under observation for pain with no evidence of perianal sepsis. The subject was treated with morphine and discharged less than 24 hours after admission.

DISCUSSION

In this study, we performed the first-in-human assessment of RD2-Ver.02 for the management of simple and complex transsphincteric anal fistulas. Interim analysis demonstrated that healing at 6 and 12 months was 69% and 60%, respectively. In addition, we found that all patients who were healed at 6 months remained healed at the 1-year follow-up mark. These findings were originally presented at the annual meeting of the American Society of Colon and Rectal Surgeons.¹⁹

In recent years, several attempts were made to create an injectable material capable of effectively and permanently closing an anal fistula tract. These included fibrin glue, plugs, mesenchymal and adipose-derived stem cells.^{20,21} However, overall success rates with these injectables have been modest, with some improvement with fistular drainage, but with a healing rate of 41.7% at 12 months.²² Outcomes for the management of complex anal fistulas with these products have been somewhat less successful with rates of 14-50%.²³ A different strategy was the anal fistula plug which was the merger of lyophilized porcine intestinal submucosa to serve as a bio-absorbable xenograft and a scaffolding material, creating a physical occlusion device for fistula

closure.²⁴ Although initial results were promising, long-term analysis indicates much more moderate rates of healing of 40-50%, especially in complex cases.^{25,26} Finally, stem cell therapy has recently gained traction in perianal Crohn's disease (CD). Long term results were published for the ADMIRE-CD trial which evaluated adipose-derived mesenchymal stem cell therapy for perianal CD, with remission rates of 56% compared to 40% in the control group.²⁷ However, the indications for stem cell therapy are fairly limited and there is little evidence on healing rates in non-CD patients. The limited success associated with these prior biologic materials coupled with the significant product related costs has degraded any evidence for cost effective benefits for anal fistula treatment.²⁸⁻³⁰ Conversely, the data suggest that RD2-Ver0.2 may be effective for both cryptoglandular and Crohn's associated transsphincteric fistula-in-ano, regardless of whether a previous attempt at fistula closure had been attempted. This therapy is potentially less risky compared with other treatments because the patient's whole blood is the principle therapeutic agent.

RD2-Ver0.2 (RedDress Ltd., Pardes Hannah-Karkur, Israel) is a novel whole-blood clot product that offers a functional extracellular matrix (ECM) to protect and facilitate tissue healing.³¹ Coagulation agents are mixed with the patient's blood to accelerate clot formation, and the resulting mixture is applied into wound cavities, allowing the coagulation process to occur inside the cavity, providing a fibrin scaffold and facilitating tissue healing.¹⁴ Since the final coagulation steps occur inside the cavity, the clot, and its beneficial factors, come into contact with the entire surface of the cavity such as anal fistula. It was proposed that the clots serve as a provisional ECM and promoting wound re-epithelialization.³² Furthermore, as the coagulation process occurs, the blood clot attaches to the exposed surface of the cavity and contracts, causing the surface to draw closer together as it forms a scaffold.

Previous studies have demonstrated the safety and efficacy of this technology in treating challenging non-healing cutaneous wounds¹²⁻¹⁷ and complex surgical wounds.³³ Using autologous blood clots, which provide a transient scaffold and recruit surrounding cells to activate wound healing³² presents a promising strategy to treat open and chronic wounds.

Study Limitations

This study shows the efficacy and safety of RD2-Ver.02 in transsphincteric perianal fistulas. The study has several limitations, mainly due to the fairly small sample of patients inherent in a pilot study. The lack of randomization and a control group limits the generalization of the results as well as any assessment of comparative effectiveness for RD2-Ver0.2. While we acknowledge the limitation of the lack of randomization and a control group in our study, it is important to discuss this issue in more detail to provide a comprehensive understanding of its implications. The absence of control subjects raises the possibility that the positive outcomes observed may not be solely attributable to our RD2-Ver0.2 product but could also be influenced by the inherent benefits of the curettage and internal opening closure procedure itself. This raises the need for a more nuanced interpretation of our findings. In addition, the study is ongoing and a subset of patients still needs to be fully assessed at one year.

Despite these limitations, healing rates of 69% in a mixed population including Crohn's disease patients and with more than half of the patients presenting with a complex fistula, is fairly impressive. The vast inclusion criteria for the study, highlights the advantages of RD2 Ver.02, which can be used in patients with different etiologies for perianal fistular disease, is easy to use, and does not require any specialized expertise from the operating surgeon for the usage of RD2-Ver.02.

CONCLUSIONS

RD2 Ver.02 treatment was found to be safe and effective in achieving healing in transsphincteric anal fistulas of both cryptoglandular and Crohn's-related origin within 6 months of treatment.

Once healed the closure appears very durable with minimal risk of recurrence. Prior therapeutic intervention does not interfere with the application of RD2-Ver.02 and potentially successful fistula closure.

Further comparative studies are needed to confirm the potential benefits of RD2-Ver.02 which represents a very safe biologic alternative for closure of transsphincteric anal fistulas.

ACKNOWLEDGMENTS

The authors would like to express their sincere gratitude to Dr. Anthony J. Senagore for his invaluable assistance and contributions to this scientific study.

ACCEPTED

REFERENCES

1. Parks AG, Gordon PH, Hardcastle JD. A classification of fistula-in-ano. *Br J Surg*. 1976;63:1–12.
2. Carr S, Velasco AL. *Fistula-in-Ano*. StatPearls Publishing; 2023.
<https://www.ncbi.nlm.nih.gov/books/NBK557517/>
3. Vogel JD, Johnson EK, Morris AM, et al. Clinical practice guideline for the management of anorectal abscess, fistula-in-ano, and rectovaginal fistula. *Dis Colon Rectum*. 2016;59:1117–1133.
4. Steele SR, Kumar R, Feingold DL, Rafferty JL, Buie WD. Practice parameters for the management of perianal abscess and fistula-in-ano. *Dis Colon Rectum*. 2011;54:1465–1474.
5. U.S. Department of Health and Human Services. Common Terminology Criteria for Adverse Events (CTCAE) Version 5.0. 2017.
https://ctep.cancer.gov/protocoldevelopment/electronic_applications/docs/ctcae_v5_quick_reference_5x7.pdf.
6. Garg P, Sodhi SS, Garg N. Management of complex cryptoglandular anal fistula: challenges and solutions. *Clin Exp Gastroenterol*. 2020;13:555–567.
7. Gaertner WB, Burgess PL, Davids JS, et al. The American Society of Colon and Rectal Surgeons Clinical Practice Guidelines for the management of anorectal abscess, fistula-in-ano, and rectovaginal fistula. *Dis Colon Rectum*. 2022;65:964–985.
8. Bubbers EJ, Cologne KG. Management of complex anal fistulas. *Clin Colon Rectal Surg*. 2016;29:43–49.

9. Göttgens KWA, Smeets RR, Stassen LPS, Beets G, Breukink SO. Systematic review and meta-analysis of surgical interventions for high cryptoglandular perianal fistula. *Int J Colorectal Dis.* 2015;30:583–593.
10. Lee JL, Yoon YS, Yu CS. Treatment strategy for perianal fistulas in crohn disease patients: the surgeon’s point of view. *Ann Coloproctol.* 2021;37:5–15.
11. García-Olmo D, Gómez-Barrera M, de la Portilla F. Surgical management of complex perianal fistula revisited in a systematic review: a critical view of available scientific evidence. *BMC Surg.* 2023;23.
12. Kushnir I, Kushnir A, Serena T, Garfinkel D. Efficacy and safety of a novel autologous wound matrix in the management of complicated, chronic wounds: a pilot study. *Wounds.* 2016;28:317–327.
13. Naude L, Idensohn P, Bruwer F, et al. An observational pilot study to collect safety and efficacy data on wound care using whole blood clot technology on hard-to-heal wounds. *Wounds International Journal.* 2021;12:42–53.
14. Snyder R, Kasper M, Patel K, et al. Safety and efficacy of an autologous blood clot product in the management of Texas 1A or 2A neuropathic diabetic foot ulcers: a prospective, multicenter, open label pilot study. *Wounds.* 2018;30:84–89.
15. Gurevich M, Wahab N, Wachuku C, Ead KJ, Snyder RJ. ActiGraft treatment in complex wounds with exposed structure - a case series. *Ann Rev Resear.* 2021;7(1):555701.
16. Williams M, Davidson D, Wahab N, Hawkins J, Wachuku CD, Snyder R. Innovative treatment utilizing an autologous blood clot for diabetic foot ulcers. *Wounds.* 2022;34.
17. Landau Z, Whitacre KL, Leewood C, Hawkins J, Wachuku CD. Utilization of a topical autologous blood clot for treatment of pressure ulcers. *Int Wound J.* 2023;20(3):806–812.

18. Rausch MK, Parekh SH, Dortdivanlioglu B, Rosales AM. Synthetic hydrogels as blood clot mimicking wound healing materials. *Prog Biomed Eng (Bristol)*. 2021;3.
19. Ram E, Zager Y, Carter D, et al. An autologous whole blood clot treatment in patients with anal fistula [ASCRS abstract S11]. *Dis Colon Rectum*. 2023;66:e361.
20. Ji L, Zhang Y, Xu L, Wei J, Weng L, Jiang J. Advances in the treatment of anal fistula: a mini-review of recent five-year clinical studies. *Front Surg*. 2021;7:586891.
21. Hjortrup A, Moesgaard F, Kjærgård J. Fibrin adhesive in the treatment of perineal fistulas. *Dis Colon Rectum*. 1991;34:752–754.
22. de la Portilla F, Muñoz-Cruzado MVD, Maestre MV, et al. Platelet-rich plasma (PRP) versus fibrin glue in cryptogenic fistula-in-ano: a phase III single-center, randomized, double-blind trial. *Int J Colorectal Dis*. 2019;34:1113–1119.
23. Swinscoe MT, Ventakasubramaniam AK, Jayne DG. Fibrin glue for fistula-in-ano: the evidence reviewed. *Tech Coloproctol*. 2005;9:89–94.
24. Van Koperen PJ, Bemelman WA, Bossuyt PM, et al. The anal fistula plug versus the mucosal advancement flap for the treatment of anorectal fistula (PLUG trial). *BMC Surg*. 2008;8:11.
25. Hansen MS, Kjær ML, Andersen J. Efficacy of plug treatment for complex anorectal fistulae: long-term Danish results. *Ann Coloproctol*. 2019;35:123–128.
26. Almeida IS, Wickramasinghe D, Weerakkody P, Samarasekera DN. Treatment of fistula in-ano with fistula plug: experience of a tertiary care centre in South Asia and comparison of results with the West. *BMC Res Notes*. 2018;11:1–5.
27. Garcia-Olmo D, Gilaberte I, Binek M, et al. Follow-up study to evaluate the long-term safety and efficacy of darvadstrocel (mesenchymal stem cell treatment) in patients with

perianal fistulizing Crohn's disease: ADMIRE-CD phase 3 randomized controlled trial. *Dis Colon Rectum*. 2022;65:713–720.

28. Jayne DG, Scholefield J, Tolan D, et al. A multicenter randomized controlled trial comparing safety, efficacy, and cost-effectiveness of the surgisis anal fistula plug versus surgeon's preference for transsphincteric fistula-in-ano: the FIAT trial. *Ann Surg*. 2021;273:433–441.
29. Eberspacher C, Mascagni D, Ferent IC, et al. Mesenchymal stem cells for cryptoglandular anal fistula: current state of art. *Front Surg*. 2022;9:815504.
30. Cheng F, Huang Z, Li Z. Efficacy and safety of mesenchymal stem cells in treatment of complex perianal fistulas: a meta-analysis. *Stem Cells Int*. 2020;2020:8816737.
31. Snyder RJ, Schultz G, Wachuku C, Rashid AM, Ead JKK. Proposed mechanism of action of topically applied autologous blood clot tissue. *J Am Podiatr Med Assoc*. 2023;113(3):20–140.
32. Serena TE, Kushnir I, Kushnir A, Yaakov RA, Eckert KA. The safety of an autologous whole blood clot product applied to full thickness dermal wounds in a porcine model for up to 18 days. *Chronic Wound Care Management and Research*. 2019;6:39–49.
33. Gurevich M, Heinz SM, Fridman R, Hawkins J, Wachuku CD. Use of autologous whole blood clot in the treatment of complex surgical wounds: a case series. *J Wound Care*. 2023;32(Suppl 2):S4–S9.

LEGENDS

Figure 1. Study flow chart.

Figure 2. Detailed description of the surgical procedure. RD2 Ver.02 procedure A) Fistula debridement with a fistula brush. B) Fistula cleaning with hydrogen peroxide. C) Suturing of the fistula internal opening. D) Water leak test. E) Preparation of RD2 Ver.02 treatment and application to the fistula cavity. F) Blockage of the outer opening with an adhesive dressing to allow the blood to coagulate inside the fistula tract. Dress the fistula and anus using the non-adherent dressing and secure it with a Medi- strip.

Figure 3. Example of a patient who presented with a complex transsphincteric fistula with 4 External Openings and treated with RD Ver. 02.

ACCEPTED

Table 1: Patients demographic and clinical characteristics.

Parameter	Values
Median Age – years (range)	42 (20-72)
Gender	
Male	41 (77.4%)
Female	12 (22.6%)
Etiologies	
Cryptoglandular Disease	44 (83.0%)
Crohn’s Disease	9 (16.9%)
Comorbidities	
Smoking	13 (24.5%)
Diabetes type 2	2 (3.7%)
Type of fistula (Preoperative MRI)	
- Simple	19 (35.8%)
- Complex	34 (64.2%)
Multiple tracts (Pre-operative MRI)	20 (37.7%)
Multiple openings	13 (24.5%)
Prior Fistula Treatment:	
Fistulotomy & Fistulectomy	7 (13.2%)
LIFT	4 (7.5%)
Other surgical procedures	10 (18.8%)

MRI – Magnetic Resonance Imaging;

Figure 1: Study flow diagram

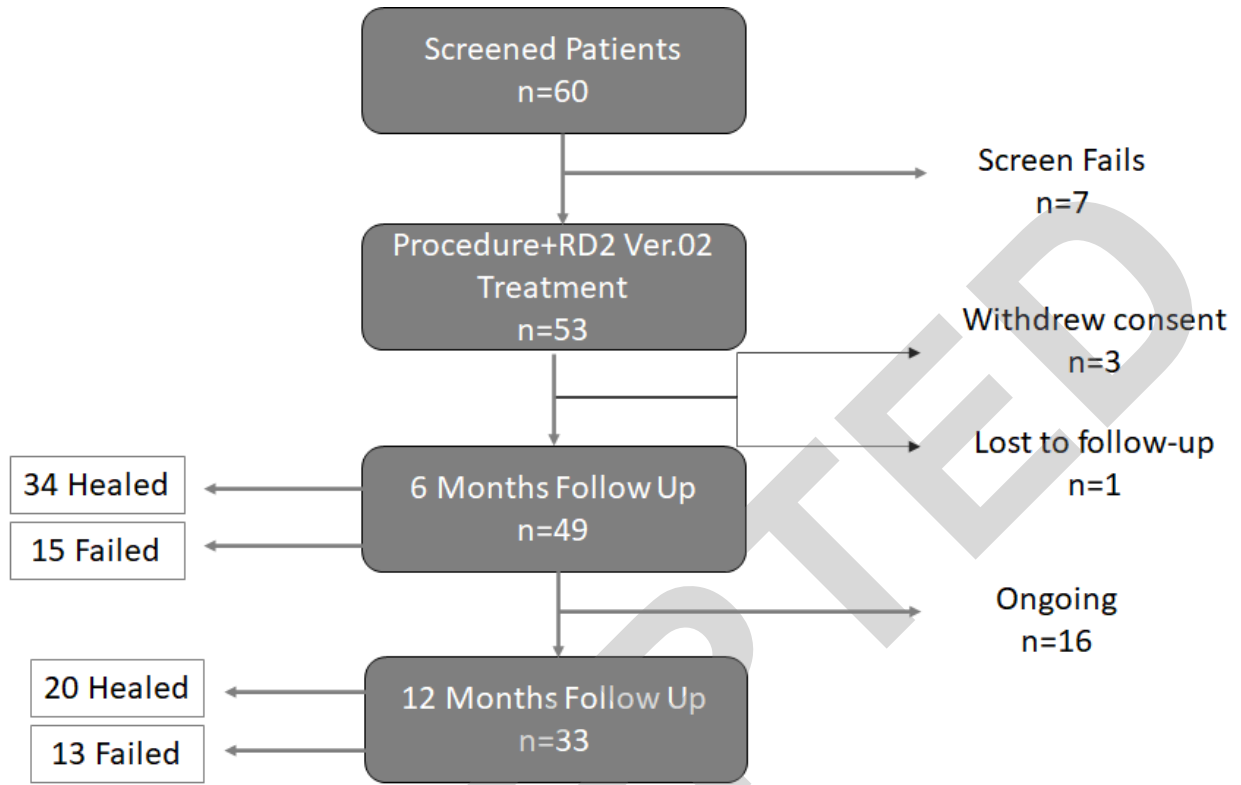


Figure 2: Detailed description of the surgical procedure. RD2 Ver.02 procedure A) Fistula debridement with a fistula brush. B) Fistula cleaning with hydrogen peroxide. C) Suturing of the fistula internal opening. D) Water leak test. E) preparation of RD2 Ver.02 treatment and application to the fistula cavity. F) Blockage of the outer opening with an adhesive dressing to allow the blood to coagulate inside the fistula tract. Dress the fistula and anus using the non-adherent dressing and secure it with a Medi- Strip.

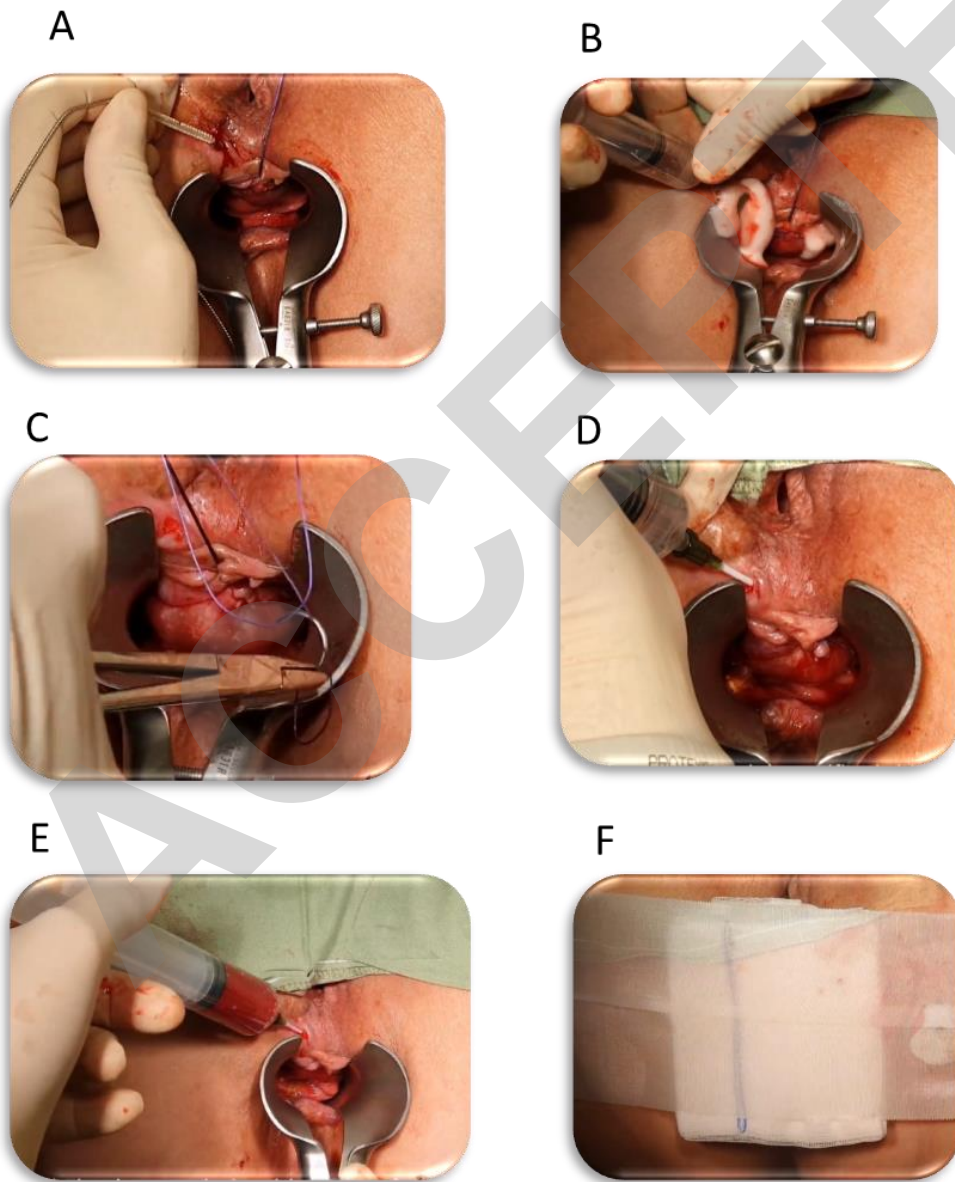
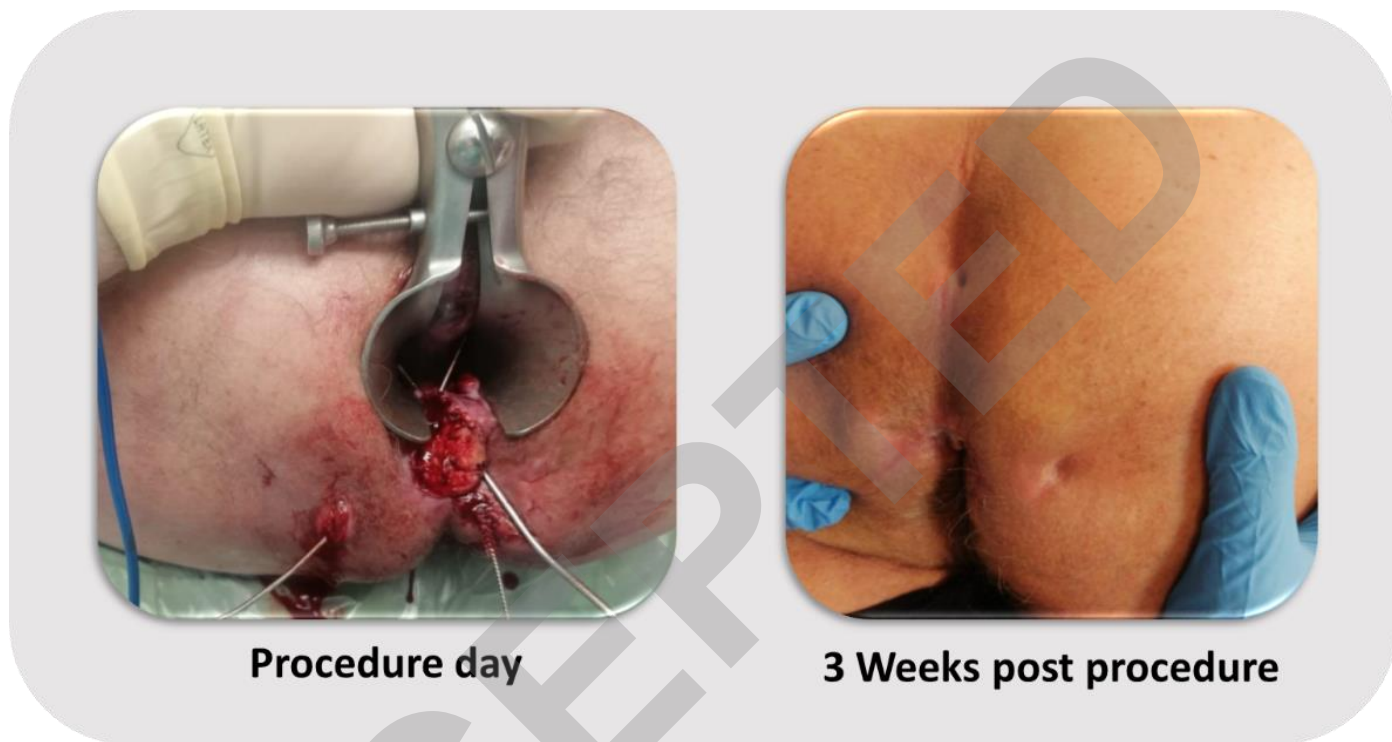

Figure 3: Example of a patients who presented with a complex transsphincteric fistula with 4 external openings and treated with RD Ver. 2.



ACCEPTED